



# MR Enterography of Crohn Disease: Part I, Rationale, Technique, and Pitfalls

Rakesh Sinha<sup>1</sup>  
Ratan Verma<sup>2</sup>  
Sadhna Verma<sup>3</sup>  
Arumugam Rajesh<sup>2</sup>

**OBJECTIVE.** The purpose of this article is to review the technique of performing MR enterography examinations and to review the imaging findings suggestive of Crohn disease. This article will also allow the reader to self-assess and improve his or her skills in the performance and interpretation of MR enterography examinations.

**CONCLUSION.** MRI plays a valuable role in providing accurate information about the severity of and complications related to Crohn disease and can help in guiding surgical or medical treatment.

**C**rohn disease is a chronic inflammatory disease of the gastrointestinal tract that runs an indolent course consisting of inflammatory exacerbation and regression. Frequent imaging examinations for monitoring disease activity and severity may be needed to achieve appropriate medical or surgical treatment. In recent years MRI has emerged as an important radiologic tool in the diagnosis and follow-up of Crohn disease. Its absence of ionizing radiation and high accuracy in detecting mural and extramural changes make MRI ideally suited for imaging patients with Crohn disease.

Although the precise cause of Crohn disease is unknown, there is evidence that the disease is due to an abnormal mucosal response to an unknown antigen [1]. Genetic factors may also be responsible because up to 5% of patients with Crohn disease have another family member affected by the disease. Patients may present after years of vague abdominal symptoms or complications such as perineal sinuses, anorectal fistulas, or abscesses. Cramping pain, often in the right lower quadrant, with frequent watery diarrhea is common. The diarrhea characterized by watery stools is caused in part by excessive secretion of fluid into a dilated loop proximal to an obstruction; loss of absorptive mucosal surface; and diseased terminal ileum, which prevents the absorption of bile salts. Chronic diarrhea is the most common presenting symptom and may be defined as a decrease in fecal consistency for more than 6 weeks as opposed to self-limited infectious diarrhea.

Abdominal pain and weight loss may be presenting symptoms in more than 60% of patients before diagnosis, whereas perineal fistulas are present in 10% of patients at the time of diagnosis [2]. Other symptoms include low-grade fever and anorexia. Deficiency of intestinal lactase sometimes leads to lactose intolerance and ileal disease, leading to vitamin B<sub>12</sub> deficiency. Rectal bleeding as a presenting symptom of Crohn disease is uncommon compared with ulcerative colitis because most cases of Crohn disease in the early stages do not have rectosigmoid involvement.

With the increasing severity of Crohn disease, there is luminal narrowing of the affected segment. The thickened edematous bowel also becomes aperistaltic, leading to obstructive symptoms. Adhesions within the mesentery and adjacent loops create further mechanical obstruction. Transmural fissuring and ulceration of the bowel may lead to extramural abscesses or fistulas. Pediatric patients may commonly present with systemic and extraintestinal symptoms rather than gastrointestinal symptoms. Iron-deficiency anemia, eating disorders, growth failure, and delayed puberty may be presenting features. Isolated gastroduodenal disease is seen more commonly in children than adults and has been reported in 30–62% of pediatric patients on endoscopy. Jejunal disease is also more common in children compared with adults [3]. In elderly individuals, Crohn disease afflicts women more frequently than men and disease involvement is more often isolated to the colon.

**Keywords:** Crohn disease, MR enterography, MRI

DOI:10.2214/AJR.10.7253

Received June 11, 2010; accepted after revision November 15, 2010.

<sup>1</sup>Department of Clinical Radiology, South Warwickshire NHS Foundation Trust, Warwick, United Kingdom.

<sup>2</sup>University Hospitals of Leicester NHS Trust, Leicester General Hospital, Gwendolen Rd, Leicester LE45PW, United Kingdom. Address correspondence to A. Rajesh (arajesh27@hotmail.com).

<sup>3</sup>Department of Radiology, University of Cincinnati Medical Center, Cincinnati, OH.

## CME/SAM

This article is available for CME/SAM Credit. See [www.arrs.org](http://www.arrs.org) for more information.

AJR 2011; 197:76–79

0361–803X/11/1971–76

© American Roentgen Ray Society

## MR Enterography

Traditionally, radiologic imaging of the small bowel relied on barium examinations or CT. However, with these investigations, the possible cumulative radiation dosage can be an adverse effect because young patients with inflammatory bowel disease may undergo several imaging examinations during the disease process. Therefore, a nonionizing investigative modality may benefit these patients.

In recent years MRI has emerged as an imaging modality that can be used in the assessment and diagnosis of Crohn disease [4–10]. The advantages of MRI include its lack of ionizing radiation and high tissue contrast resolution. The other strengths of MRI are its ability to provide accurate anatomic detail; depict extraintestinal abnormalities; and facilitate distinction between phlegmon, abscesses, and mesenteric lymphadenopathy.

MR fluoroscopy can also be performed to assess stricture and obstruction. Recently, work has been done on perfusion MRI and parameters to assess for recurrent inflammation and fibrosis, respectively. Although there is not enough evidence to suggest that MRI can reliably identify early mucosal ulcers, a recent review has highlighted the value of high-resolution MRI in the detection of early ulceration [11]. The sensitivity and specificity values of MRI for the detection of

Crohn disease have been reported in scientific studies to range from 88% to 98% and from 78% to 100%, respectively [12–15].

MR enterography examinations combine the spatial and temporal resolution of MRI with large volumes of ingested oral contrast material to obtain luminal distention. The oral intake of contrast medium obviates nasojejunal intubation, and although the enterographic technique may be less discomfiting for the patient, it may not produce similar distention of the bowel as can be obtained by an MR enteroclysis examination. However, studies have shown that an MR enterography examination can provide diagnostic accuracy similar to that obtained with an MR enteroclysis examination [16, 17].

The MR enterography examination may be associated with greater patient tolerance and acceptability than enteroclysis examinations and has the potential to become an important imaging technique in the diagnostic workup of patients with suspected small-bowel disease. Investigators have reported excellent patient tolerance of the MR enterography technique and high sensitivity and specificity in a subgroup of pediatric patients with Crohn disease [18–20].

## Technique

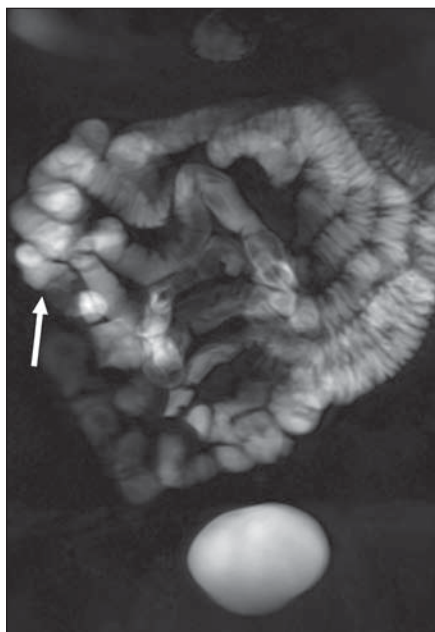
A combination of good bowel distention and ultrafast MRI sequences is required to obtain diagnostic small-bowel images. Several enteral contrast agents have been described including water; methylcellulose; or solutions containing locust bean gum, mannitol, or polyethylene glycol [21]. These agents work by retarding the resorption of water in the intestine. Continuous, steady ingestion of the oral contrast material over a period of minutes can produce homogeneous opacification of the entire small-bowel lumen.

Our specific protocol for MR enterography requires that the patient fast for 6 hours before the procedure. Fasting decreases the amount of food residue and debris in the intestinal lumen that can be mistaken for mass lesions or polyps. Unless contraindicated, patients also follow a low-residue diet for the preceding 5 days. A low-residue diet promotes reduction of fecal matter in the colon, which facilitates transit of the small-bowel contrast agent because fecal material can delay transit times in the small bowel.

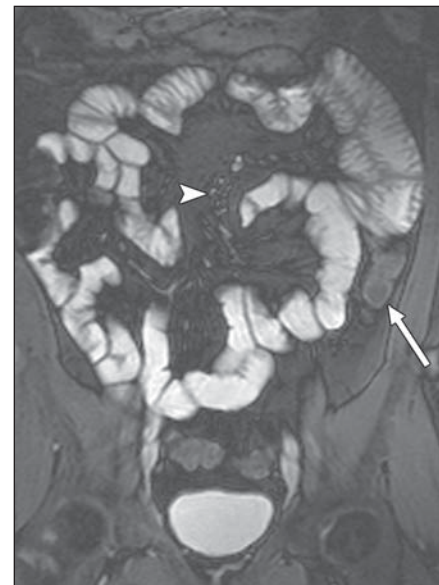On arrival to the department, the patient ingests 1200–1300 mL of an isoosmotic solution of water mixed with polyethylene glycol and electrolytes (Klean-Prep, Helsinn) or of

water mixed with mannitol to produce a 3% solution. The oral contrast material is divided in two aliquots of 600–650 mL each, and the patient drinks one aliquot every 25–30 minutes. Ingesting the contrast solution over the allocated time period is of paramount importance because delayed ingestion can result in most of the contrast filling the colon, whereas reduced ingestion of the contrast agent can lead to suboptimal small-bowel distention. The ingestion of two aliquots of oral contrast solution over a prolonged period (50–60 minutes) promotes uniform and consistent filling of the proximal and distal small bowel. An oral suspension that contains 10 mg of metoclopramide is given with the first aliquot to promote gastric emptying. Just before imaging, patients are asked to drink another 200 mL of contrast material to opacify the stomach and duodenum.

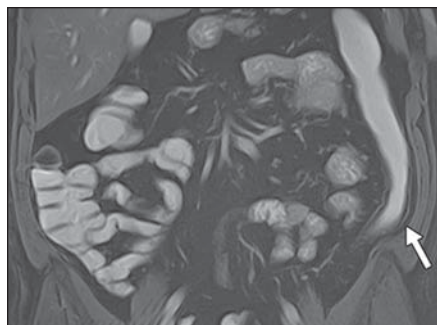
After completion of the oral phase, patients are imaged using a thick-slab (50-mm) HASTE sequence (Fig. 1). This provides a single-shot image of opacified small bowel that helps determine whether the oral contrast agent has reached the ileocecal junction. Once the contrast material reaches the ileocecal junction, an IV injection of 1 mg of glucagon is administered to minimize bowel peristalsis. If bowel obstruction is observed on thick-slab HASTE images, MR fluoroscopy of the



**Fig. 1**—45-year-old man with suspected Crohn disease. Coronal thick-slab HASTE image (50-mm thickness) shows good opacification of proximal and distal small bowel up to ileocecal junction and ascending colon (arrow).



**Fig. 2**—45-year-old man with suspected Crohn disease (same patient as shown in Fig. 1). Coronal true fast imaging with steady-state precession image (4-mm thickness) shows distended bowel loops. Note black boundary artifact along bowel wall (arrow) and mesenteric vessels (arrowhead) that obscure detailed evaluation of periintestinal space.



**Fig. 3**—35-year-old man with suspected Crohn disease. Coronal true fast imaging with steady-state precession image with fat saturation (4-mm thickness) shows good opacification of proximal and distal small bowel up to ileocecal junction. High contrast is achieved between lumen, mesentery, and bowel wall. Note clear visualization of bowel wall (arrow) and lack of black boundary artifact.

affected segment may be performed to assess for inflammatory adhesions or strictures before injection of antiperistaltic drugs.

Imaging of the distended bowel is performed using ultrafast MR sequences based on steady-state precession. Different vendors term these sequences as true fast imaging with steady-state precession (FISP), balanced fast field-echo, or fast imaging employing steady-state precession. These sequences are relatively insensitive to motion artifacts and provide high contrast between

the bowel wall, lumen, and mesentery. The main disadvantage of these sequences is a black boundary artifact along the bowel wall that may mask small lesions or abnormalities; however, fat suppression helps in reducing the effects of this artifact (Figs. 2 and 3). The major advantage of the ultrafast MRI sequences is the ability to acquire abdominal images within a single breath-hold.

T2-weighted sequences based on RARE are also used. These sequences are termed “HASTE,” or “single-shot fast spin-echo,” and they produce high contrast between the lumen and the bowel wall and may enable visualization of ulcers, mural edema, and collections with greater facility. These sequences do not suffer from the black boundary artifact, although they are susceptible to motion artifacts produced by flow void.

Either 2D or 3D spoiled gradient-echo T1-weighted sequences are used to acquire contrast-enhanced images. Contrast-enhanced sequences using 2D and 3D FLASH or volumetric sequences, such as volumetric interpolated breath-hold examination, are then performed to assess the enhancement pattern of the bowel (Fig. 4). At our institution, we also obtain high-resolution images with contiguous thin sections (2–3 mm thick) with a small field of view (160–250 mm), which provides high-quality multiplanar images

[11]. The imaging plane in these sequences is aligned parallel to the bowel segments to allow detailed visualization of mucosal irregularities and is aligned perpendicular to the bowel to provide accurate visualization of transmural ulcers, fistulas, sinus tracts, and periintestinal abnormalities. MR fluoroscopy is performed as needed with cine true FISP sequences and a frame rate of 0.5–2 sections per second along the long axis of the affected segments.

### Pitfalls

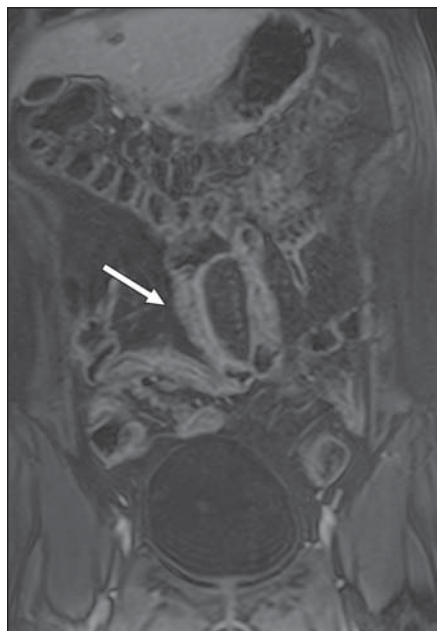
Although MR enterography may be more palatable to patients rather than intubation, suboptimal distention of bowel loops can be encountered more commonly. Early mural changes of Crohn disease may be overlooked in areas of collapsed bowel segments. Partial strictures may also not be identified because of inadequate distention of the bowel. Artifacts due to peristalsis or flow voids are more prominent on HASTE sequences (Fig. 5). Intraluminal food debris may simulate filling defects or polyps; a low-residue diet and fasting before examination help in reducing these artifacts. Previous surgery, particularly stricturoplasty, may mimic tumors with a shouldered margin or fibrotic strictures. Observation of these segments in all three planes helps in distinguishing stricturoplasties from tumors because stricturoplasties typically have a lobulated or bi- or trifoliate appearance.

### Conclusion

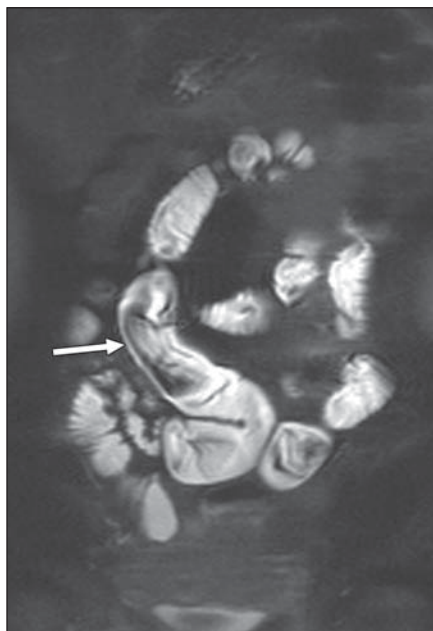
The advantages of MRI include its high sensitivity in the diagnosis of Crohn disease and its important role in the assessment of inflammatory activity. Its ability to distinguish fibrotic from inflammatory strictures and its high sensitivity for detecting abscesses and fistulas are the other advantages of MRI that can help in guiding treatment of patients. Its nonionizing nature is also a particular advantage in patients who undergo repeated imaging investigations.

### References

1. Wills JS, Lobis IF, Denstman FJ. Crohn disease: state of the art. *Radiology* 1997; 202:597–610
2. Stange EF, Travis SP, Vermeire S, et al.; European Crohn's and Colitis Organisation. European evidence-based consensus on the diagnosis and management of Crohn's disease: definitions and diagnosis. *Gut* 2006; 55[suppl 1]:i1–i15
3. Sinha R, Murphy P, Hawker P, Sanders S, Rajesh A, Verma R. Role of MRI in Crohn's disease. *Clin Radiol* 2009; 64:341–352



**Fig. 4**—27-year-old man with suspected Crohn disease. Coronal volumetric interpolated breath-hold examination image with fat saturation (2.5-mm thickness) shows intense enhancement of inflamed segment of ileum (arrow).



**Fig. 5**—35-year-old man with suspected Crohn disease. Coronal HASTE image with fat saturation (4-mm thickness) shows linear filling defect in bowel lumen (arrow) due to peristalsis.



## Imaging Gastrointestinal Tract Torsions

4. Prassopoulos P, Papanikolaou N, Grammatikakis J, Rousomoustakaki M, Maris T, Gourtsoyiannis N. MR enteroclysis imaging of Crohn disease. *RadioGraphics* 2001; 21(spec no.):S161–S172
5. Sinha R, Nwokolo C, Murphy PD. Magnetic resonance imaging in Crohn's disease. *BMJ* 2008; 336:273–276
6. Masselli G, Brizi G, Parrella A, Minordi L, Vecchioli A, Marano P. Crohn disease: magnetic resonance enteroclysis. *Abdom Imaging* 2004; 29: 326–334
7. Masselli G, Casciani E, Poletti E, Lanciotti S, Bertini L, Gualdi G. Assessment of Crohn's disease in the small bowel: prospective comparison of magnetic resonance enteroclysis with conventional enteroclysis. *Eur Radiol* 2006; 16:2817–2827
8. Schmidt S, Lepori D, Meuwly J, et al. Prospective comparison of MR enteroclysis with multidetector spiral-CT enteroclysis: interobserver agreement and sensitivity by means of "sign-by-sign" correlation. *Eur Radiol* 2003; 13:1303–1311
9. Schreyer AG, Geissler A, Albrich H, et al. Abdominal MRI after enteroclysis or with oral contrast in patients with suspected or proven Crohn's disease. *Clin Gastroenterol Hepatol* 2004; 2:491–497
10. Schreyer AG, Scheibl K, Heiss P, Feuerbach S, Seitz J, Herfarth H. MR colonography in inflammatory bowel disease. *Abdom Imaging* 2006; 31:302–307
11. Sinha R, Rajiah P, Murphy P, Hawker P, Sanders S. Utility of high-resolution MR imaging in showing transmural pathologic changes in Crohn disease. *RadioGraphics* 2009; 29:1847–1867
12. Horsthuis K, Stokkers PC, Stoker J. Detection of inflammatory bowel disease: diagnostic performance of cross-sectional imaging modalities. *Abdom Imaging* 2008; 33:407–416
13. Horsthuis K, Bipat S, Bennink RJ, Stoker J. Inflammatory bowel disease diagnosed with US, MR, scintigraphy, and CT: meta-analysis of prospective studies. *Radiology* 2008; 247:64–79
14. Gourtsoyiannis N, Papanikolaou N, Grammatikakis J, Papamastorakis G, Prassopoulos P, Rousomoustakaki M. Assessment of Crohn's disease activity in the small bowel with MR and conventional enteroclysis: preliminary results. *Eur Radiol* 2004; 14:1017–1024
15. Gourtsoyiannis N, Grammatikakis J, Papamastorakis G, et al. Imaging of small intestinal Crohn's disease: comparison between MR enteroclysis and conventional enteroclysis. *Eur Radiol* 2006; 16:1915–1925
16. Negaard A, Paulsen V, Sandvik L, et al. A prospective randomized comparison between two MRI studies of the small bowel in Crohn's disease, the oral contrast method and MR enteroclysis. *Eur Radiol* 2007; 17:2294–2301
17. Negaard A, Sandvik L, Berstad AE, et al. MRI of the small bowel with oral contrast or nasojejunal intubation in Crohn's disease: randomized comparison of patient acceptance. *Scand J Gastroenterol* 2008; 43:44–51
18. Godefroy C, Pilleul F, Dugougeat F, et al. Value of contrast-enhanced MR enterography in pediatric Crohn's disease: preliminary study [in French]. *J Radiol* 2005; 86:1685–1692
19. Pilleul F, Godefroy C, Yzebe-Beziat D, Dugougeat-Pilleul F, Lachaux A, Valette P. Magnetic resonance imaging in Crohn's disease. *Gastroenterol Clin Biol* 2005; 29:803–808
20. Hohl C, Haage P, Krombach GA, et al. Diagnostic evaluation of chronic inflammatory intestinal diseases in children and adolescents: MRI with true-FISP as new gold standard? [in German] *Rofo* 2005; 177:856–863
21. Kuehle CA, Ajaj W, Ladd SC, Massing S, Barkhausen J, Lauenstein TC. Hydro-MRI of the small bowel: effect of contrast volume, timing of contrast administration, and data acquisition on bowel distention. *AJR* 2006; 187:1000; [web] W375–W385

### FOR YOUR INFORMATION

The Self-Assessment Module accompanying this article can be accessed via [www.ajronline.org](http://www.ajronline.org) at the article link labelled "CME/SAM."

The American Roentgen Ray Society is pleased to present these Self-Assessment Modules (SAMs) as part of its commitment to lifelong learning for radiologists. Each SAM is composed of two journal articles along with questions, solutions, and references, which can be found online. Read each article, then answer the accompanying questions and review the solutions online. After submitting your responses, you'll receive immediate feedback and benchmarking data to enable you to assess your results against your peers.

Continuing medical education (CME) and SAM credits are available in each issue of the *AJR* and are **free to ARRS members. Not a member?** Call 1-866-940-2777 (from the U.S. or Canada) or 703-729-3353 to speak to an ARRS membership specialist and begin enjoying the benefits of ARRS membership today!